

# Novel Treatment Strategies for Severely Calcified Coronary Arteries



David Geffen  
School of Medicine



Michael S. Lee, MD, FACC, FSCAI  
Associate Professor  
Interventional Cardiology

# 80 year-old diabetic with ACS

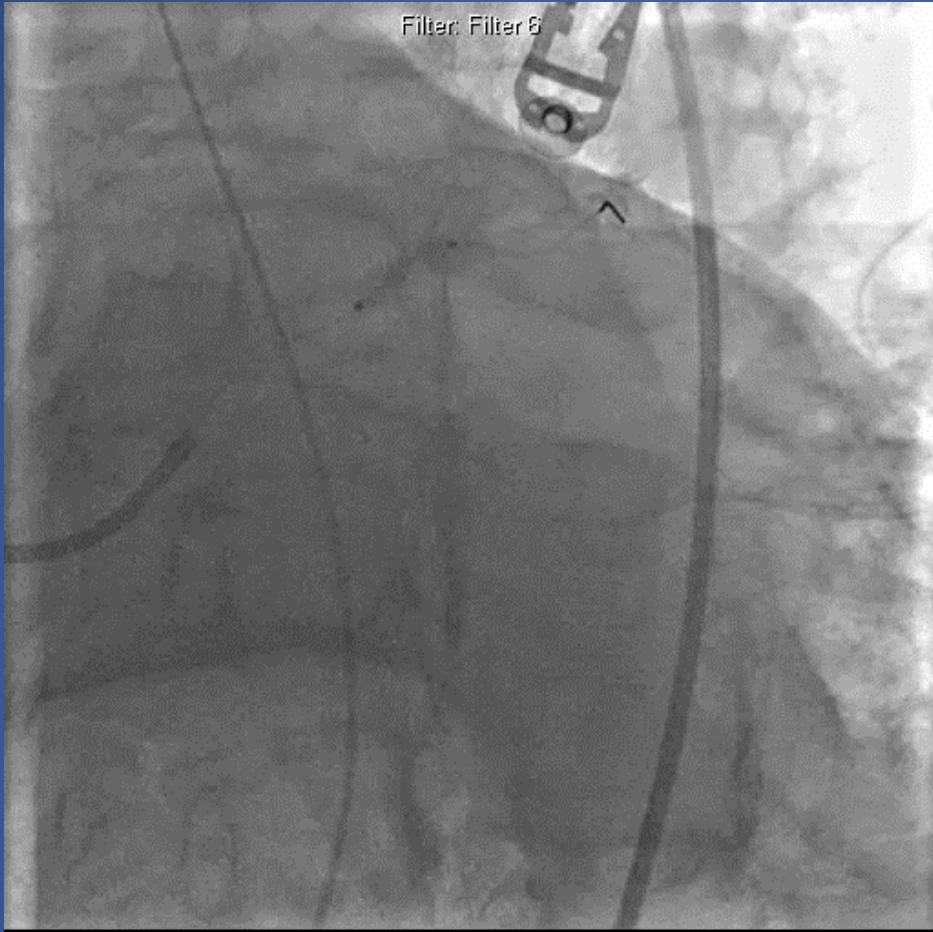
Filter: Filter 6

Filter: Filter 6

**Severely calcified proximal LAD**

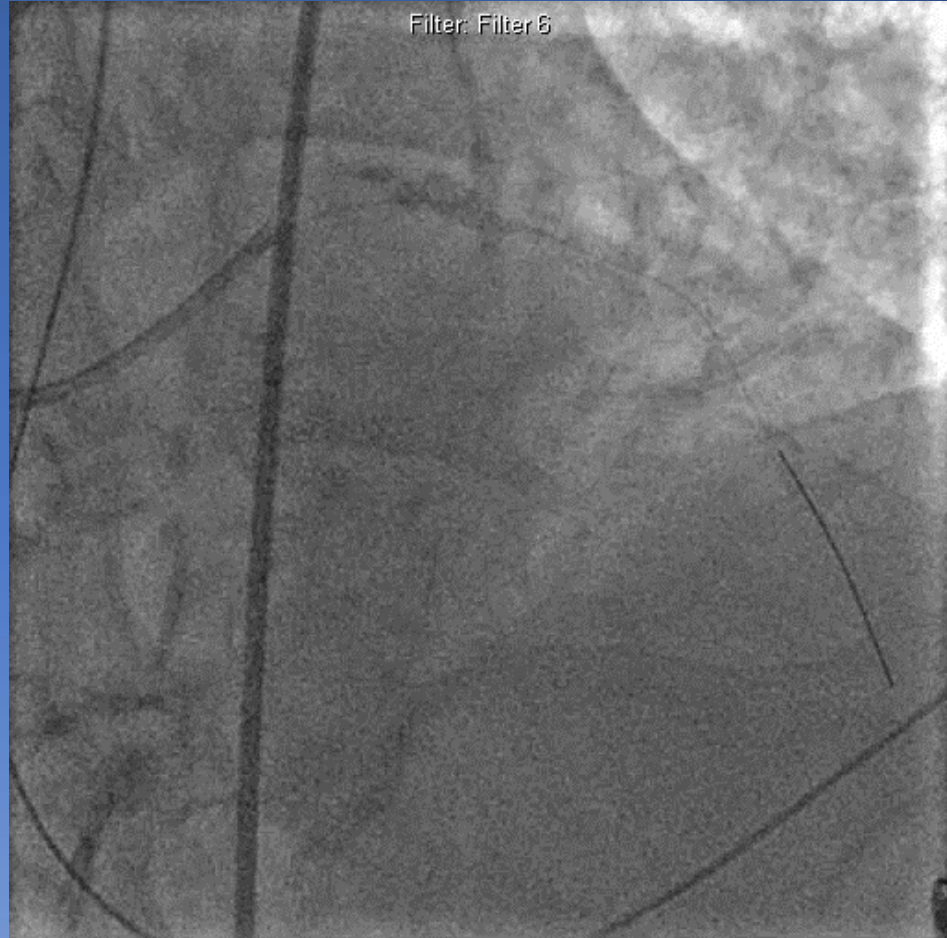


Filter: Filter 6



- Multiple, prolonged, high-pressure inflations
- Unable to fully dilate balloon

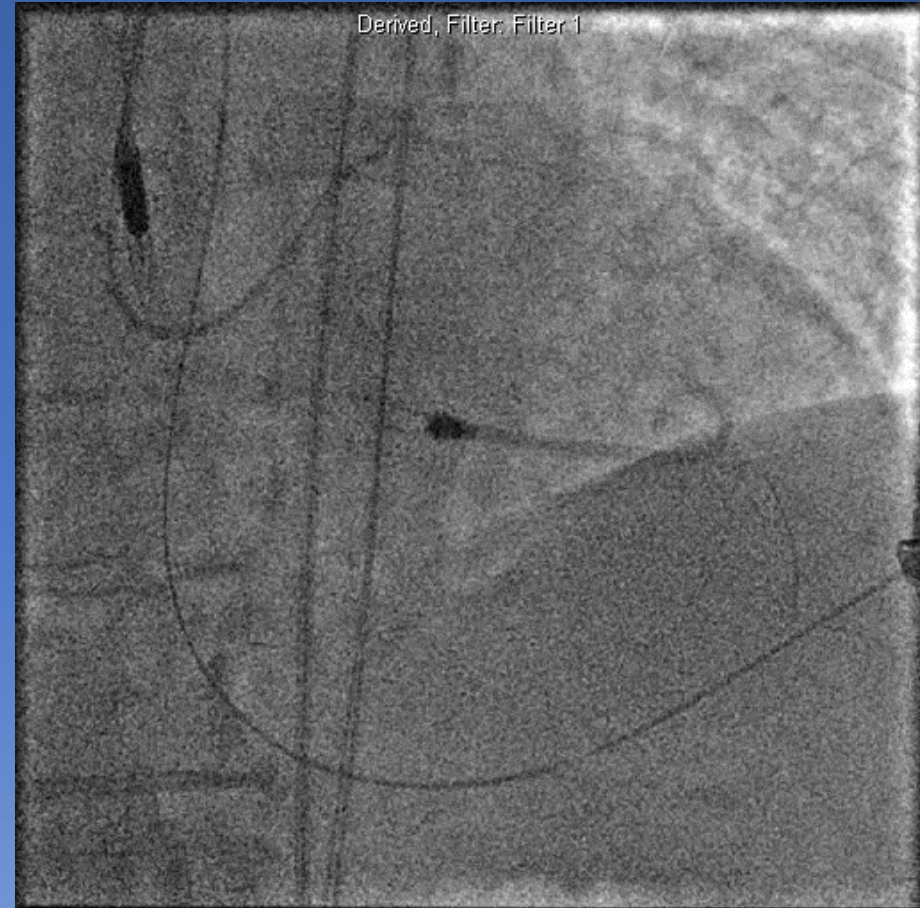
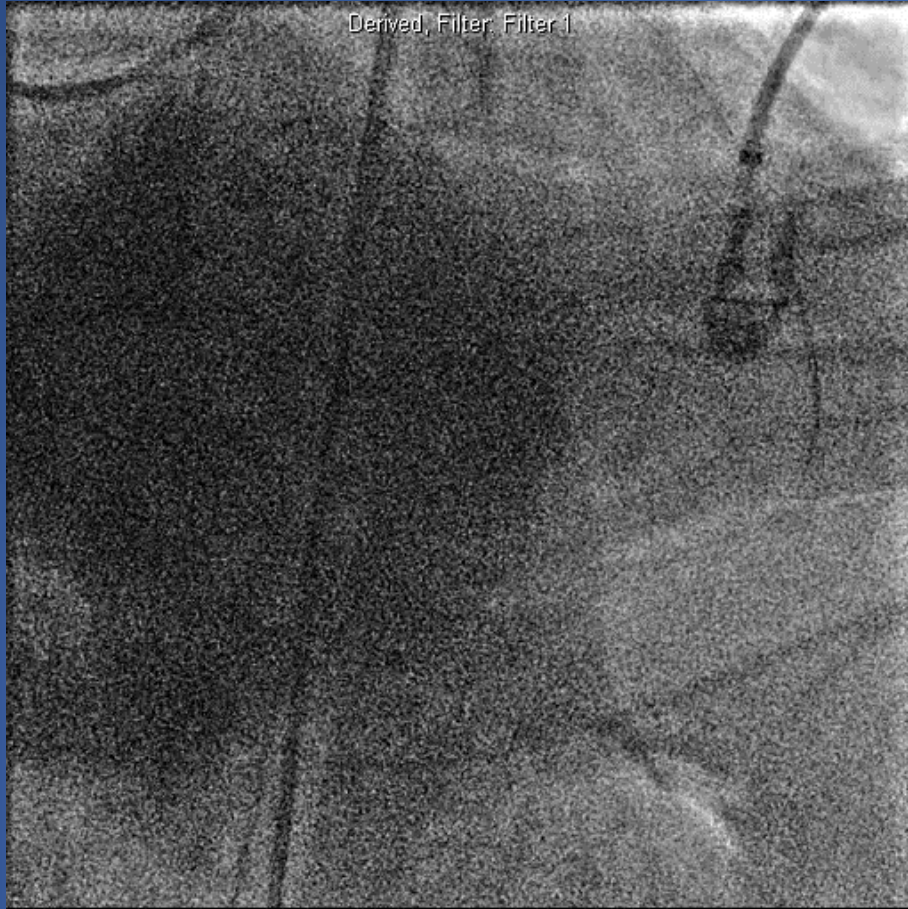
Filter: Filter 6



- Slow flow
- Ischemia
- Contrast staining c/w dissection

- **Cardiac arrest**
- **CPR**

- **Impella insertion**
- **Rotational atherectomy**



- **Intubated, multiple vasopressors**
- **Hemo-metabolic shock, septic shock, multi-organ failure**
- **Died**

# Coronary Artery Calcium *a 40-year old problem*

## The New England Journal of Medicine

©Copyright, 1979, by the Massachusetts Medical Society

Volume 301

JULY 12, 1979

Number 2

### NONOPERATIVE DILATATION OF CORONARY-ARTERY STENOSIS

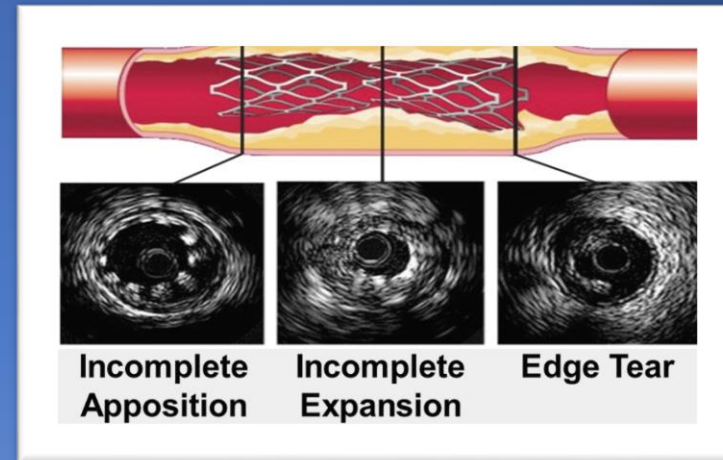
#### Percutaneous Transluminal Coronary Angioplasty

ANDREAS R. GRÜNTZIG, M.D., ÅKE SENNING, M.D., AND WALTER E. SIEGENTHALER, M.D.

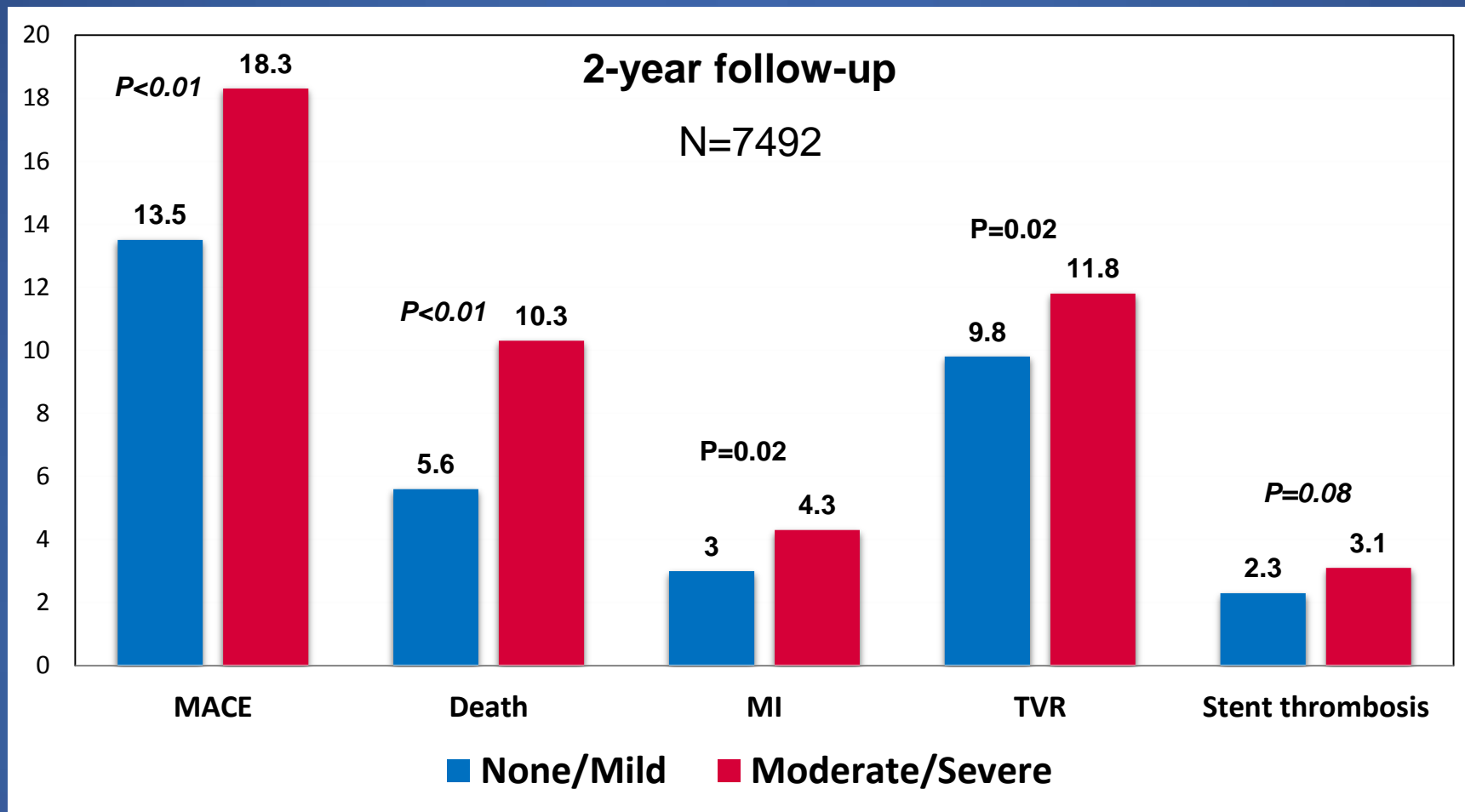
*'At present, the [balloon-dilatation] technique is limited by anatomic factors, such as ... calcified stenoses.'<sup>1</sup>*

# Challenges with Calcified Lesions

- **Difficult to treat**
  - Difficult to dilate
  - Prone to dissection during angioplasty
  - Difficulty delivering stent
  - Prevent adequate stent expansion
- **Poor clinical outcomes, including higher MACE**
  - Most trials excluded calcified lesions



# Impact of Coronary Artery Calcification in PCI with PES *ARRIVE I and II Registries*



# Rationale for Plaque Preparation with Coronary Atherectomy

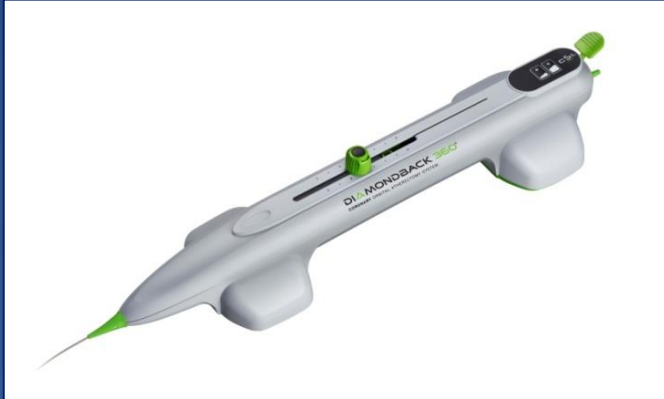
- Improve procedural success
- Change morphology of lesion
- Facilitates optimal stent expansion
- Reduce complications





# Orbital Atherectomy

## Mechanism of Action



### Differential Sanding:

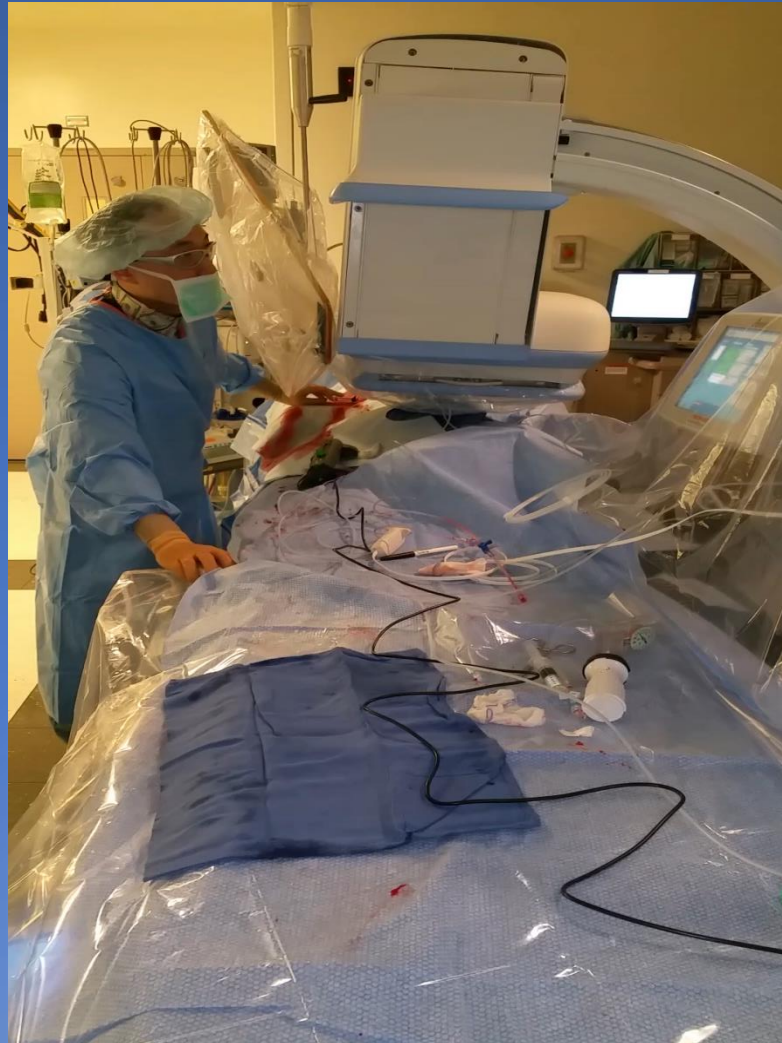
- 30 micron diamond coating
- Bi-directional sanding, eccentric mounted crown
- Healthy elastic tissue flexes away minimizing damage to the vessel

### Centrifugal Force:

- 360° crown contact designed to create a smooth, concentric lumen
- Allows constant blood flow and particulate flushing during orbit
- Increasing speed increases orbital diameter
- Ability to treat multiple vessel diameters with one crown (1.25 mm)
- Treat large vessels through small sheaths (6 French)



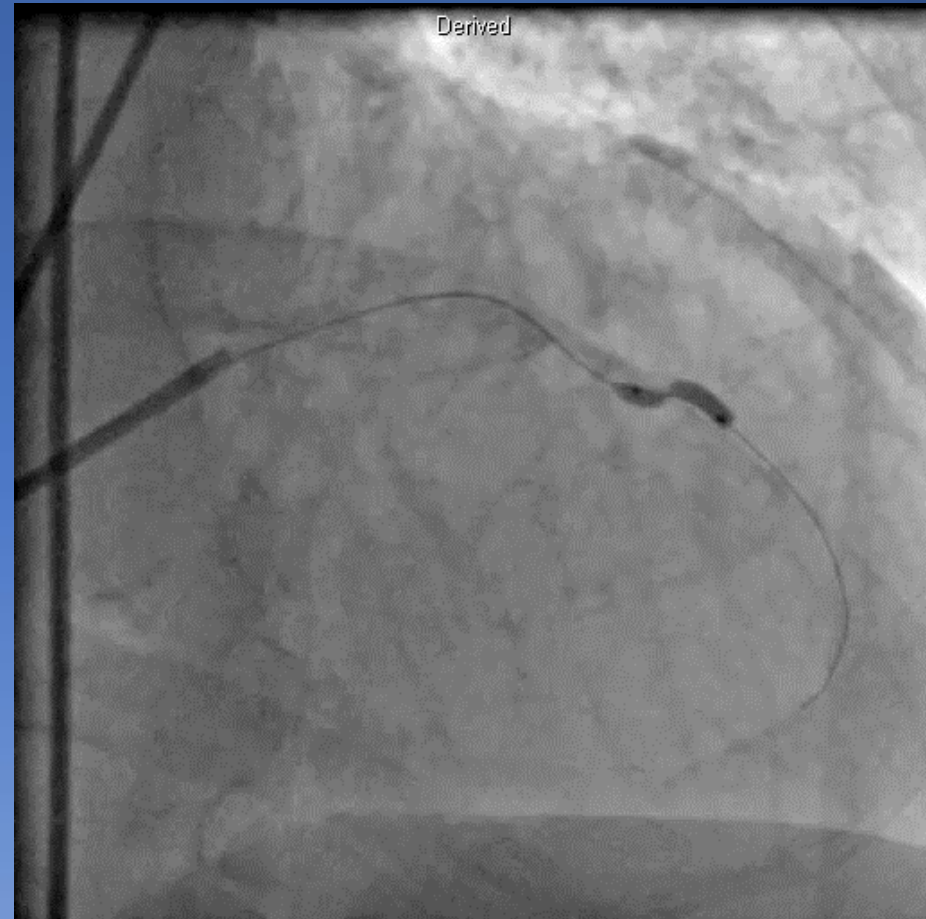
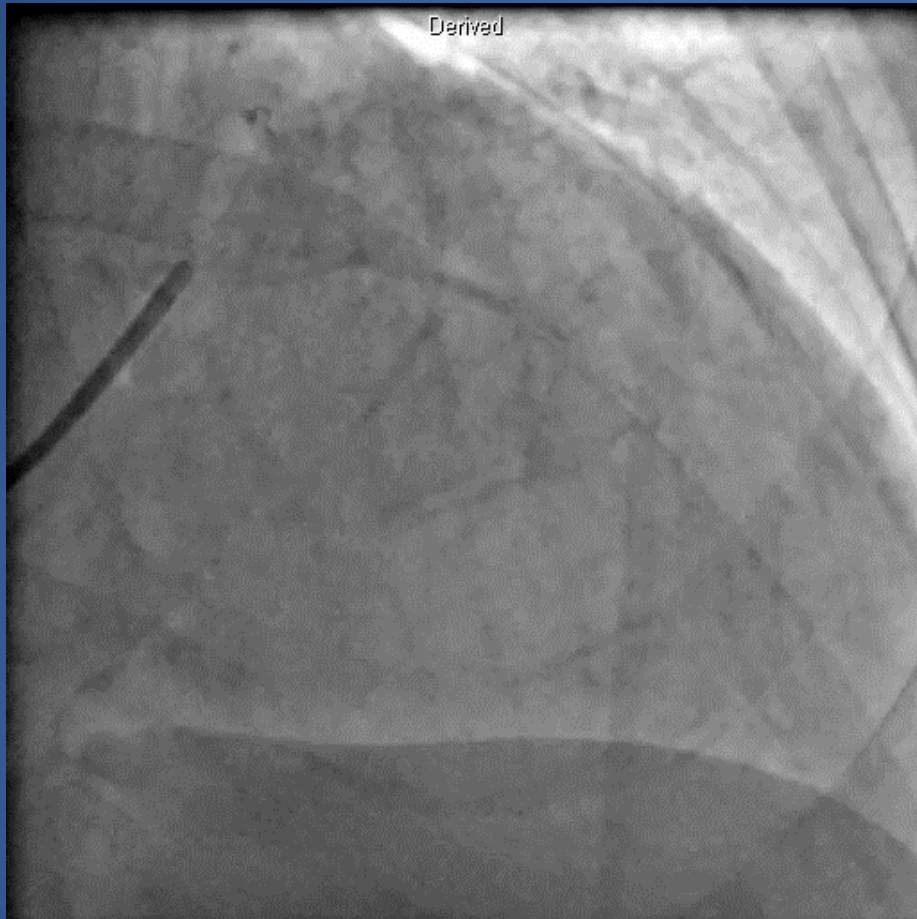
# Single-Operator Technique



Lee MS, et al. J Invasive Cardiol 2016.

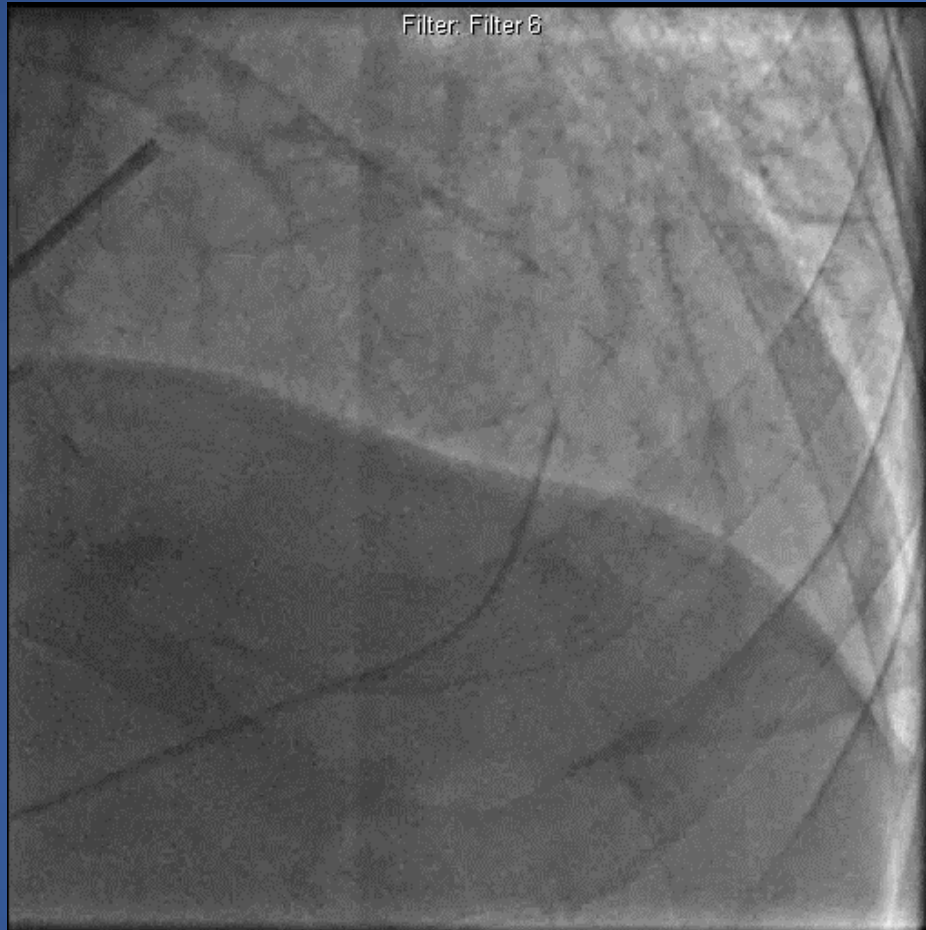
UCLA Health

**76 y.o. male with unstable angina**  
**PMH: smoking, HTN**

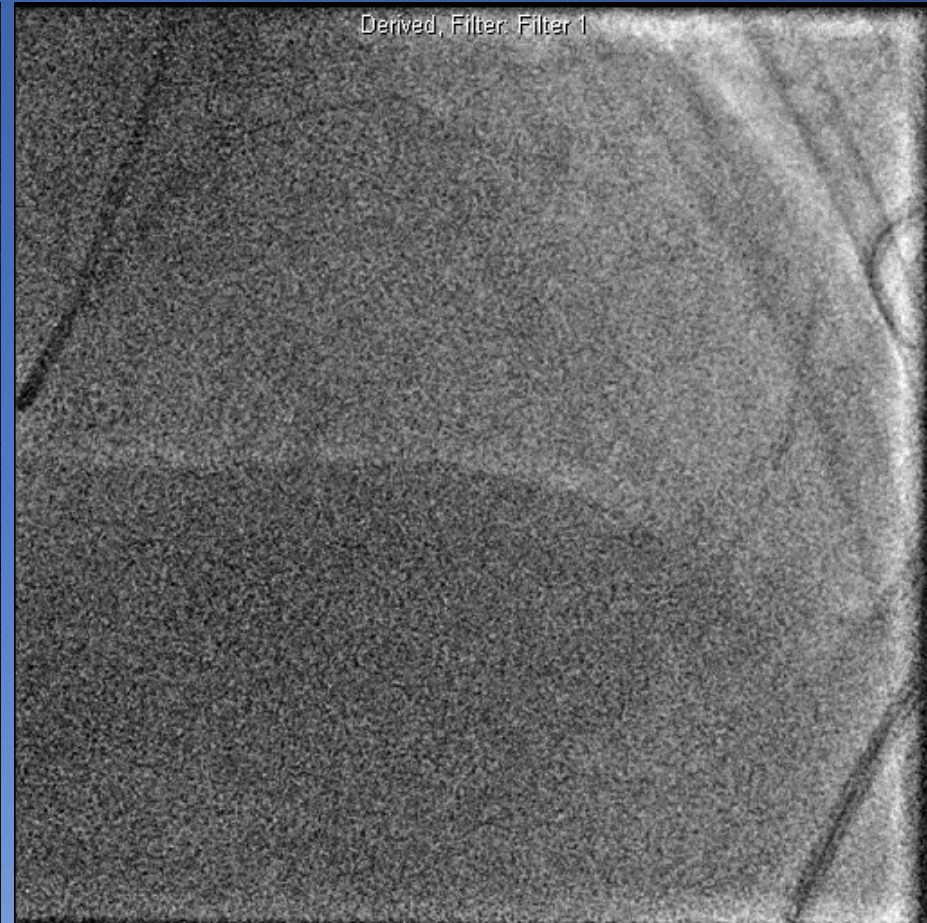


**Severe proximal LAD stenosis**

**Unable to dilate calcified lesion**



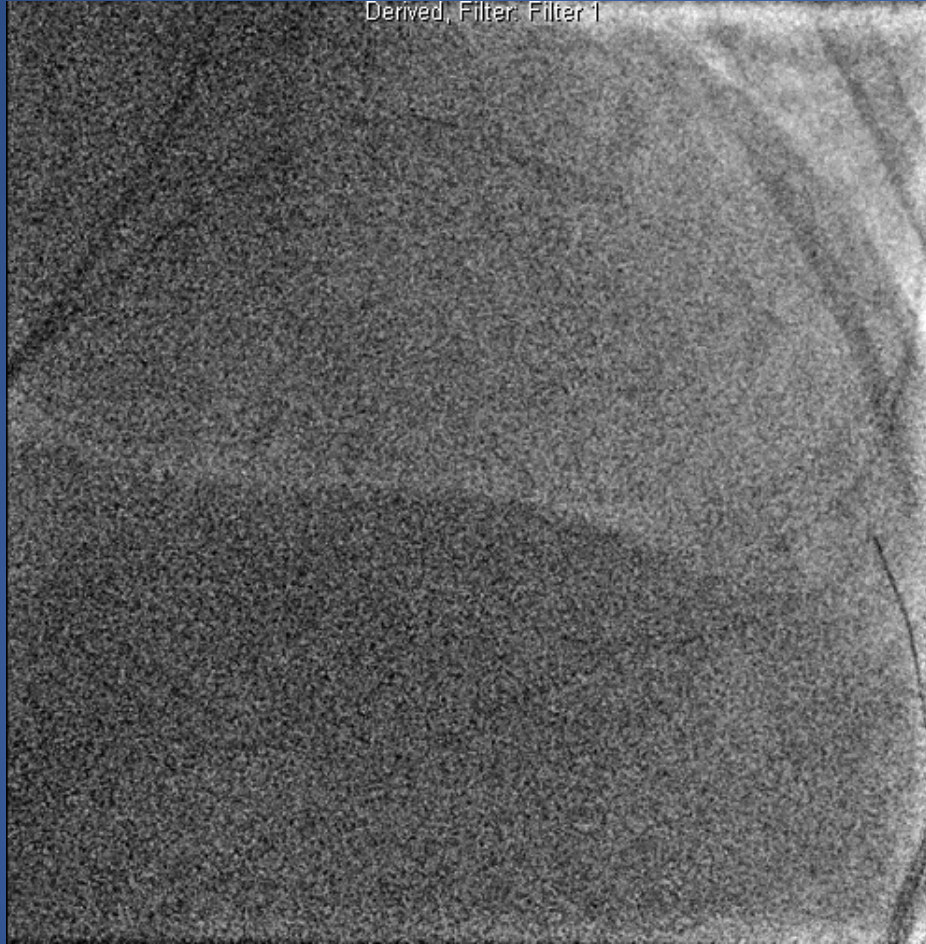
**Angiography at 1 week shows pseudo-aneurysm of LAD**



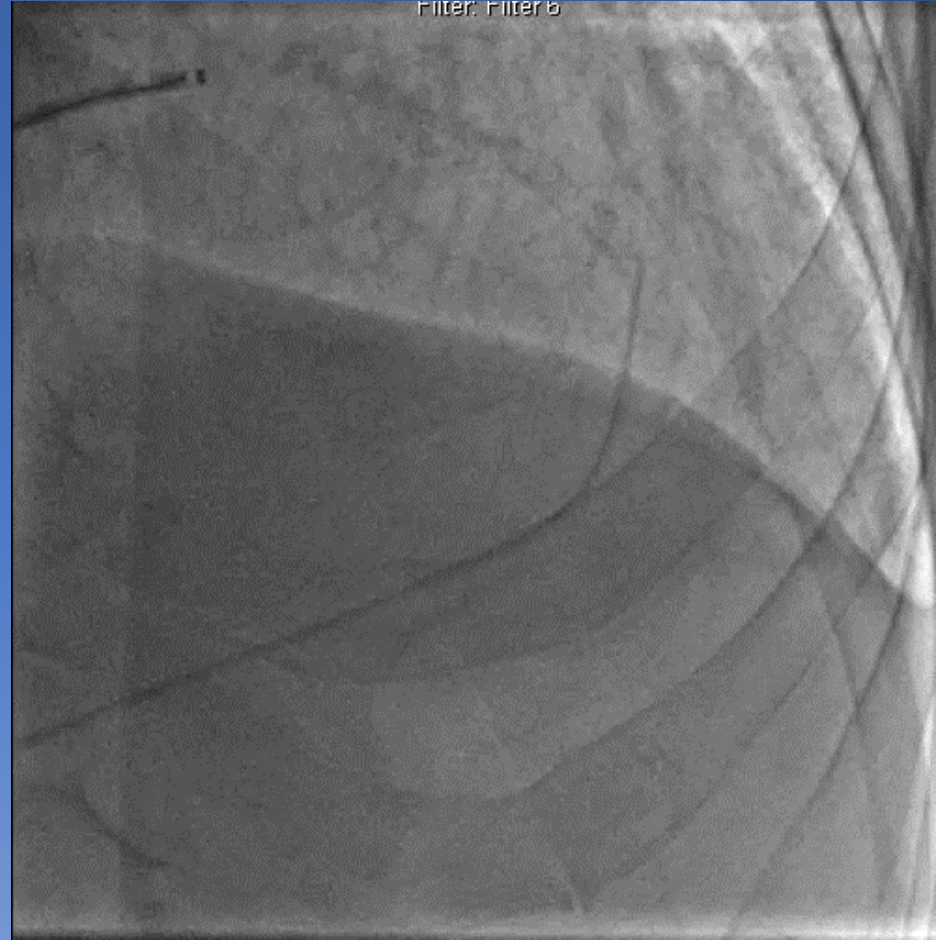**Difficulty wiring**

# *Look, Listen, and Feel*

Derived, Filter: Filter 1



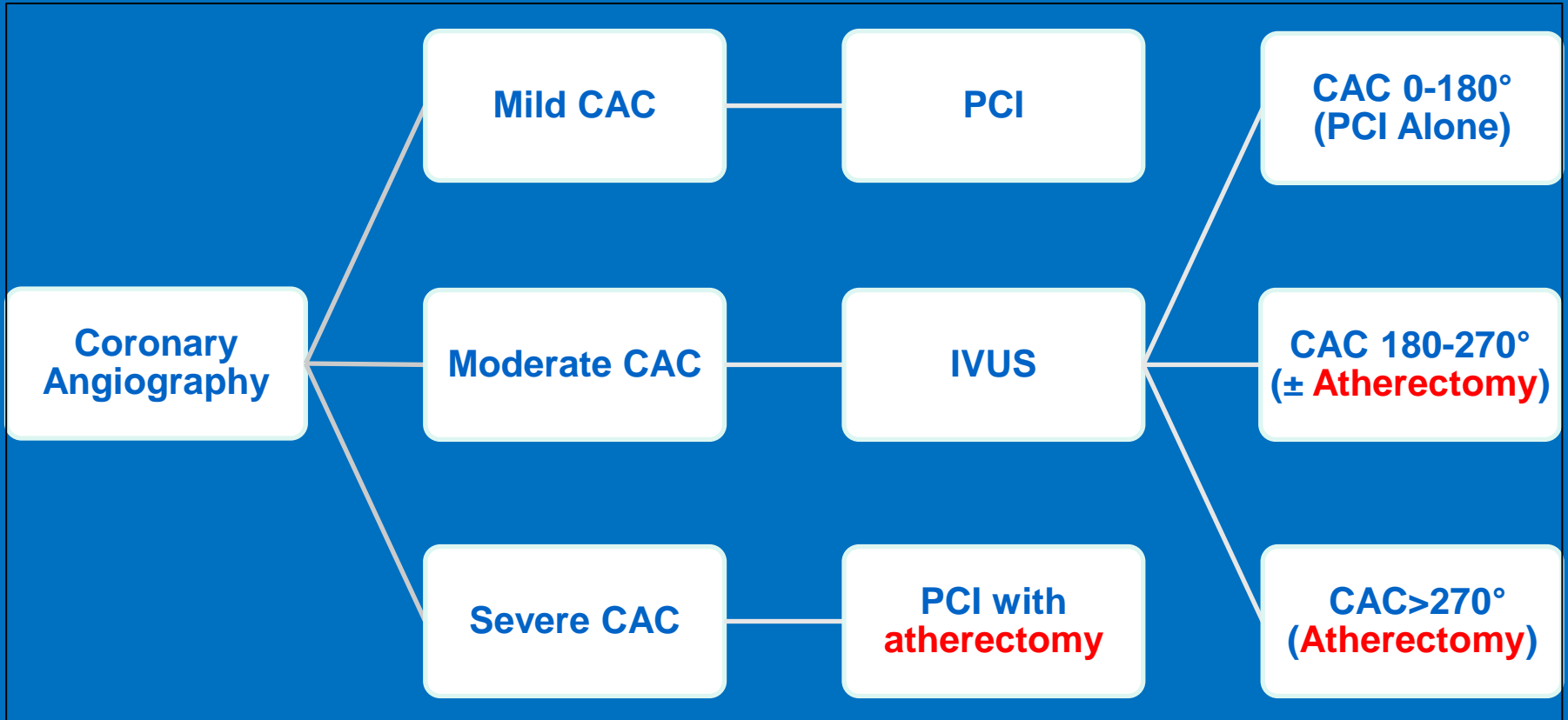
Filter: Filter 6



- Advance 1 mm/second. Max 25 seconds
- Continue low-speed until change in cadence
- Slow, pecking. Never push

**Final angiography**

# Orbital Atherectomy



# ORBIT II: Study Design

To evaluate safety and efficacy of the Diamondback Coronary OAS Classic Crown to prepare *de novo*, **severely calcified coronary lesions** for enabling stent placement

- Prospective, multi-center trial in the United States
- Single arm - As there were no FDA-approved percutaneous treatments specifically for patients with severely calcified coronary lesions.
- **443 subjects enrolled at 49 U.S. Sites**

30 day  
follow-up\*  
(N=437/440)

1-year  
follow-up†  
(N=434/440)

2-year  
follow-up‡  
(N=424/440)

3-year  
follow-up#  
(N=411/440)

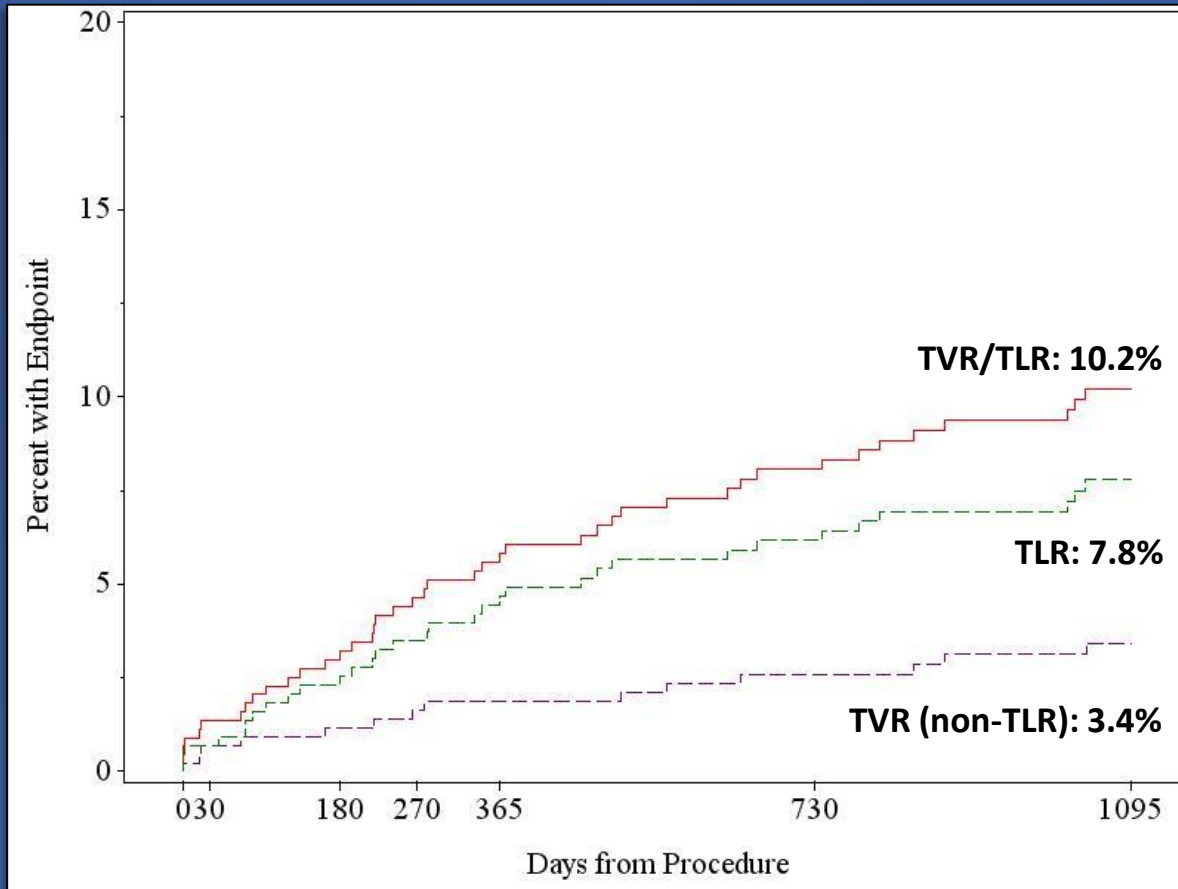
- **Primary Safety Endpoint: MACE** (MI= CK-MB>3x ULN, TVR, Cardiac Death)
- **Primary Efficacy Endpoint: Procedural Success**
  - Success in facilitating stent delivery with a final residual stenosis of <50% (as determined by Angiographic Core Lab) and free from in-hospital MACE

\*438 subjects per Kaplan Meier were at risk/events for MACE  
†432 subjects per Kaplan Meier were at risk/events for MACE  
‡411 subjects per Kaplan Meier were at risk/events for MACE  
#311 subjects per Kaplan Meier were at risk/events for MACE  
Lee MS, et al. Cardiovasc Revasc Med. 2017;18:261-264.



# ORBIT II

## 3-Year TVR/TLR



Number at risk (TVR/TLR)	443	430	413	403	392	356	228
Number at risk (TLR)	443	432	415	407	396	363	234
Number at risk (TVR)	443	433	421	416	407	377	242



# Real-World Multicenter Experience on Patients with Severe Coronary Artery Calcification Undergoing Orbital Atherectomy

## Participating Sites

- Retrospective study
- 458 consecutive patients with severe CAC who underwent orbital atherectomy followed by stenting
- October 2013 to December 2015

**Ucla**



St. Francis Hospital  
The Heart Center  
Catholic Health Services  
At the heart of health



# Angiographic Complications

© 2016, Wiley Periodicals, Inc.  
DOI: 10.1111/joic.12310

## ORIGINAL INVESTIGATION

### Real-World Multicenter Registry of Patients with Severe Coronary Artery Calcification Undergoing Orbital Atherectomy

MICHAEL S. LEE, M.D.,<sup>1</sup> EVAN SHLOFMITZ, D.O.,<sup>2</sup> BARRY KAPLAN, M.D.,<sup>2</sup>  
DRAGOS ALEXANDRU, M.D.,<sup>2</sup> PERWAIZ MERAJ, M.D.,<sup>2</sup> and RICHARD SHLOFMITZ, M.D.<sup>3</sup>

From the <sup>1</sup>Division of Interventional Cardiology, UCLA Medical Center, Los Angeles, California; <sup>2</sup>Division of Cardiology, Northwell Health, Manhasset, New York; and <sup>3</sup>Division of Cardiology, St. Francis Hospital, Roslyn, New York

**Objectives:** We evaluated the safety and efficacy of orbital atherectomy in real-world patients with severe coronary artery calcification (CAC).

**Background:** The presence of severe CAC increases the complexity of percutaneous coronary intervention as it may impede stent delivery and optimal stent expansion. Atherectomy may be an indispensable tool for uncrossable or undilatable lesions by modifying severe CAC. Although the ORBIT I and II trials report that orbital atherectomy was safe and effective for the treatment of severe CAC, patients with kidney disease, recent myocardial infarction, long diffuse disease, severe left ventricular dysfunction, and unprotected left main disease were excluded.

**Methods:** This retrospective study included 458 consecutive patients with severe CAC who underwent orbital atherectomy followed by stenting from October 2013 to December 2015 at 3 centers.

**Results:** The primary endpoint of major adverse cardiac and cerebrovascular events at 30 days was 1.7%. Low rates of 30-day all-cause mortality (1.3%), myocardial infarction (1.1%), target vessel revascularization (0%), stroke (0.2%), and stent thrombosis (0.9%) were observed. Angiographic complications were low: perforation was 0.7%, dissection 0.9%, and no-reflow 0.7%. Emergency coronary artery bypass graft surgery was performed in 0.2% of patients.

**Conclusion:** In the largest real-world study of patients who underwent orbital atherectomy, including high-risk patients who were not surgical candidates as well as those with very complex coronary anatomy, acute and short-term adverse clinical event rates were low. A randomized clinical trial is needed to identify the ideal treatment strategy for patients with severe CAC. (J Intervent Cardiol 2016;9999:1–6)

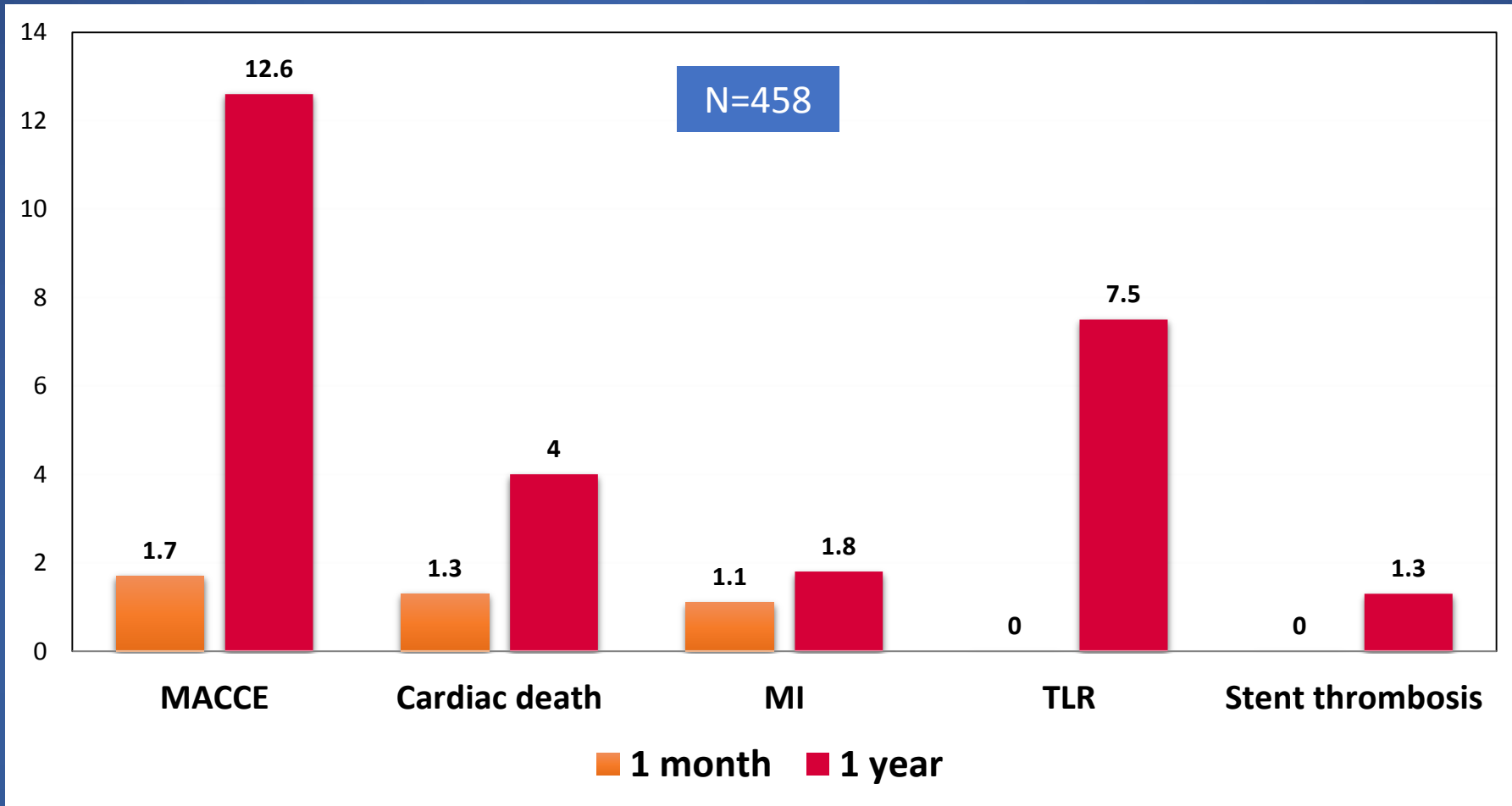
	n=458
Perforation	3 (0.7%)
Dissection	4 (0.9%)
No reflow	3 (0.7%)



Lee MS, et al. J Interv Cardiol 2016.

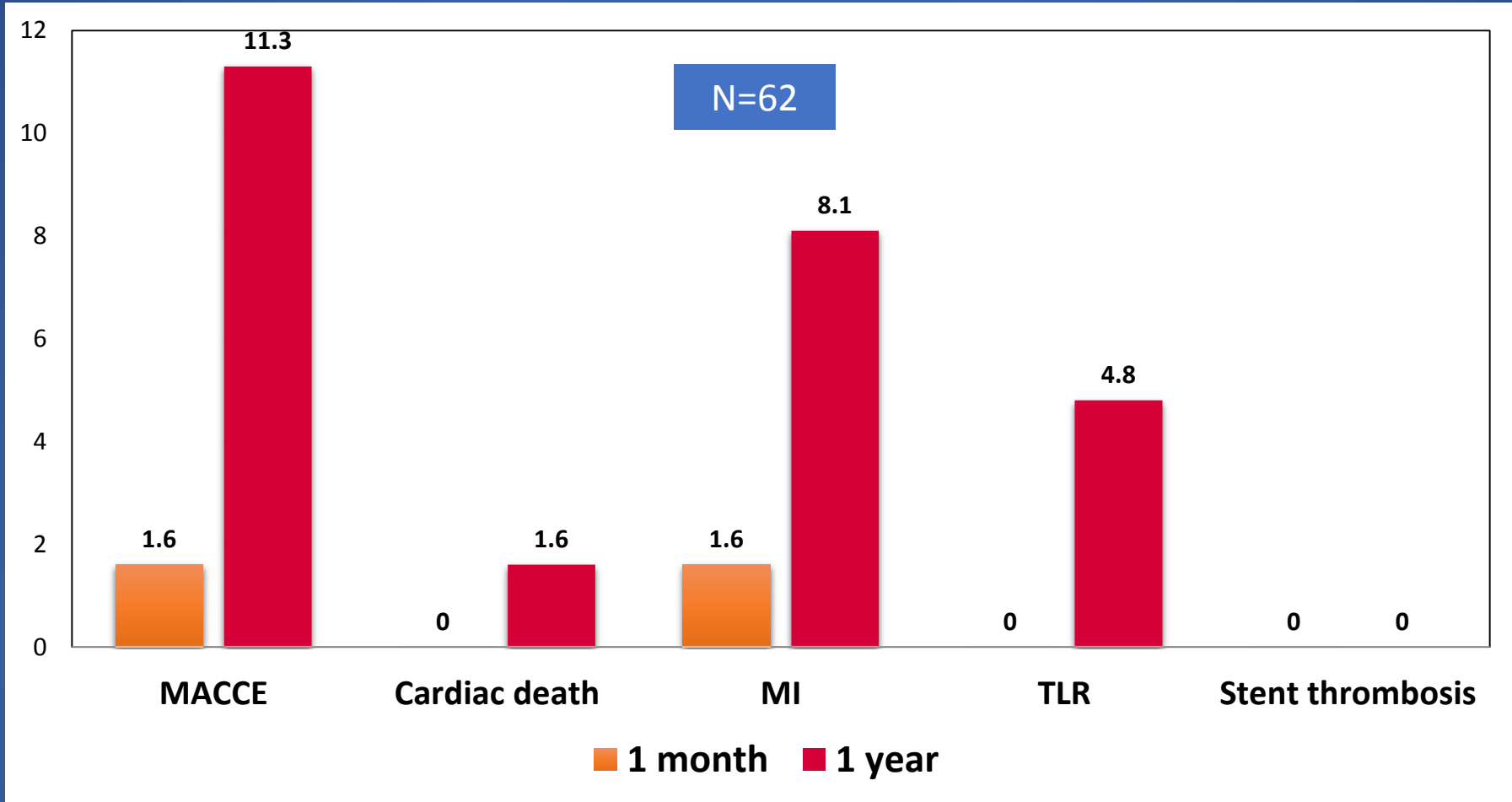


# Orbital Atherectomy 30-day and 1-year follow-up

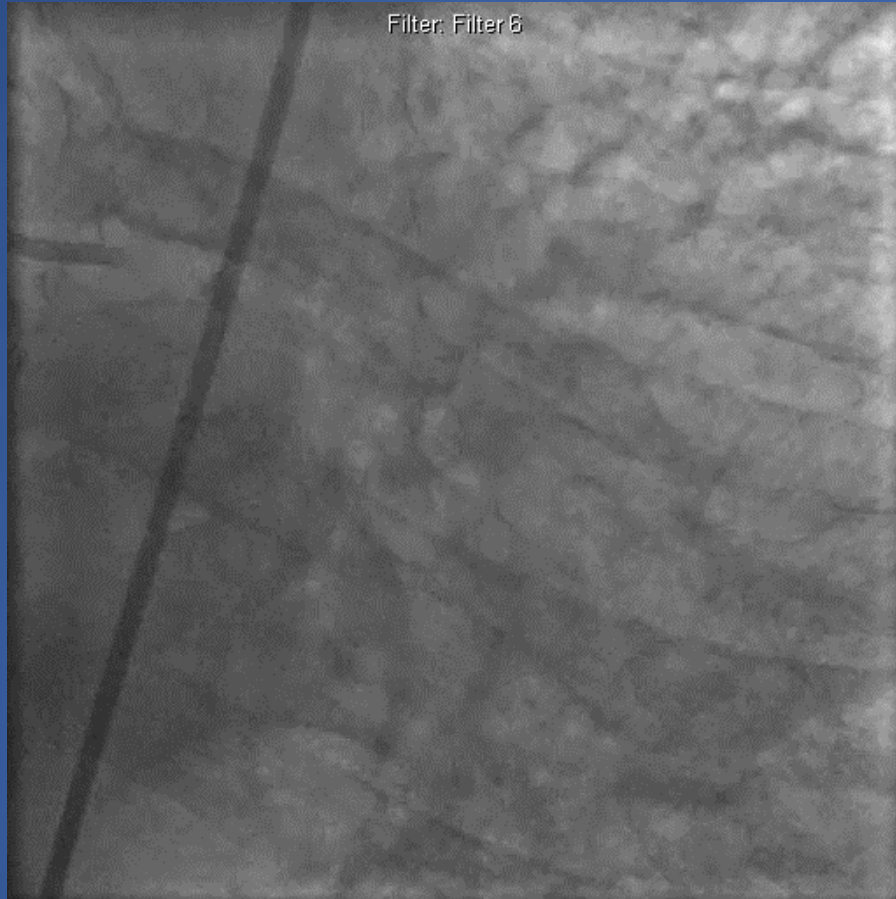


Lee MS, et al. J Interv Cardiol 2016  
Lee MS, et al. J Invasive Cardiol 2018

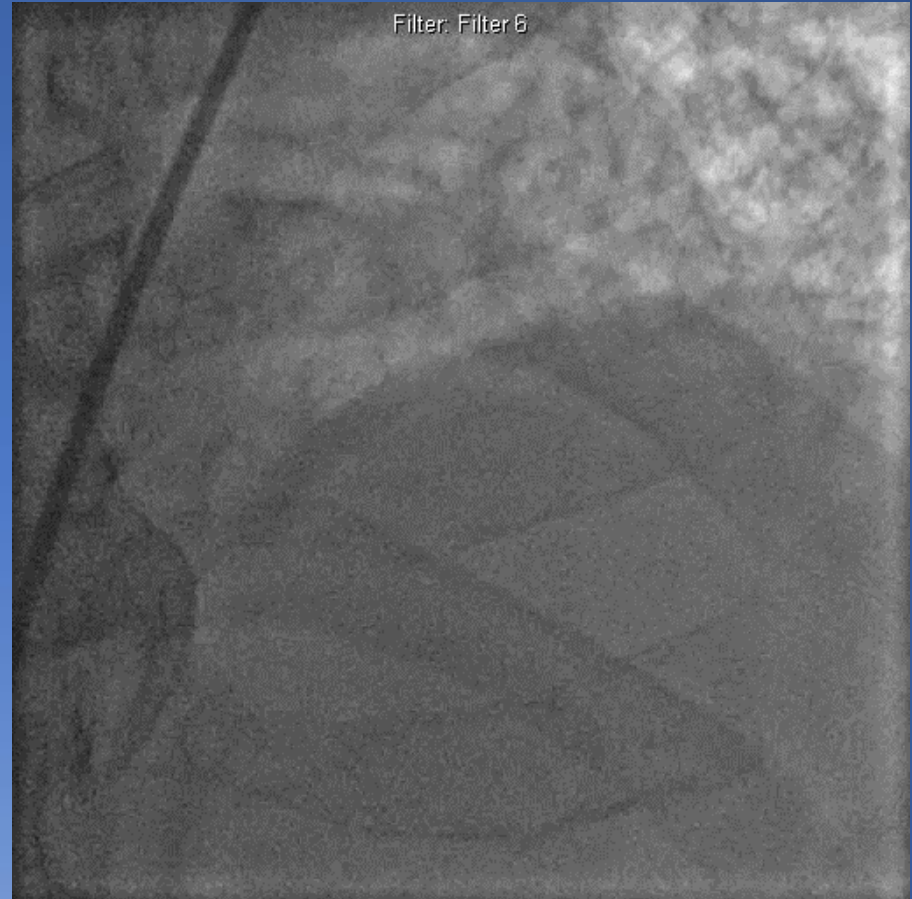
# Orbital Atherectomy for Unprotected Left Main Disease



# Calcified Left Main and LAD





**68 y.o. male pre-lung transplant**



**Calcified LM and LAD**

# Orbital Atherectomy Left Main Artery

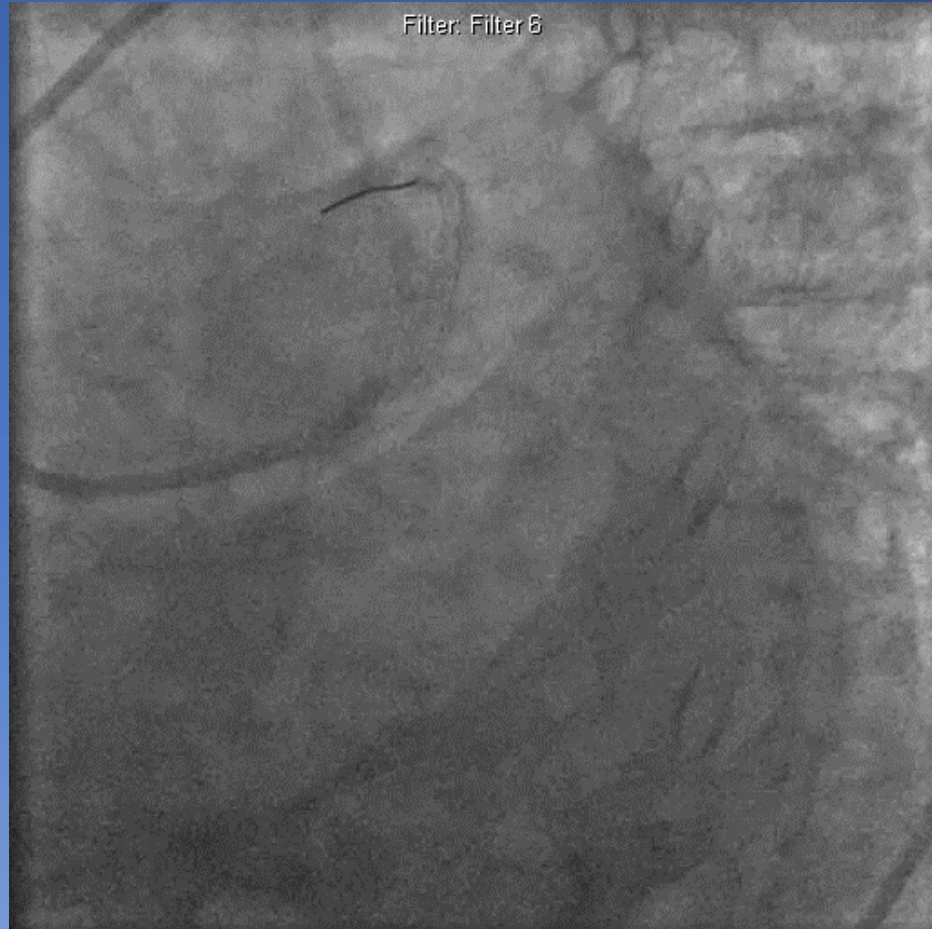
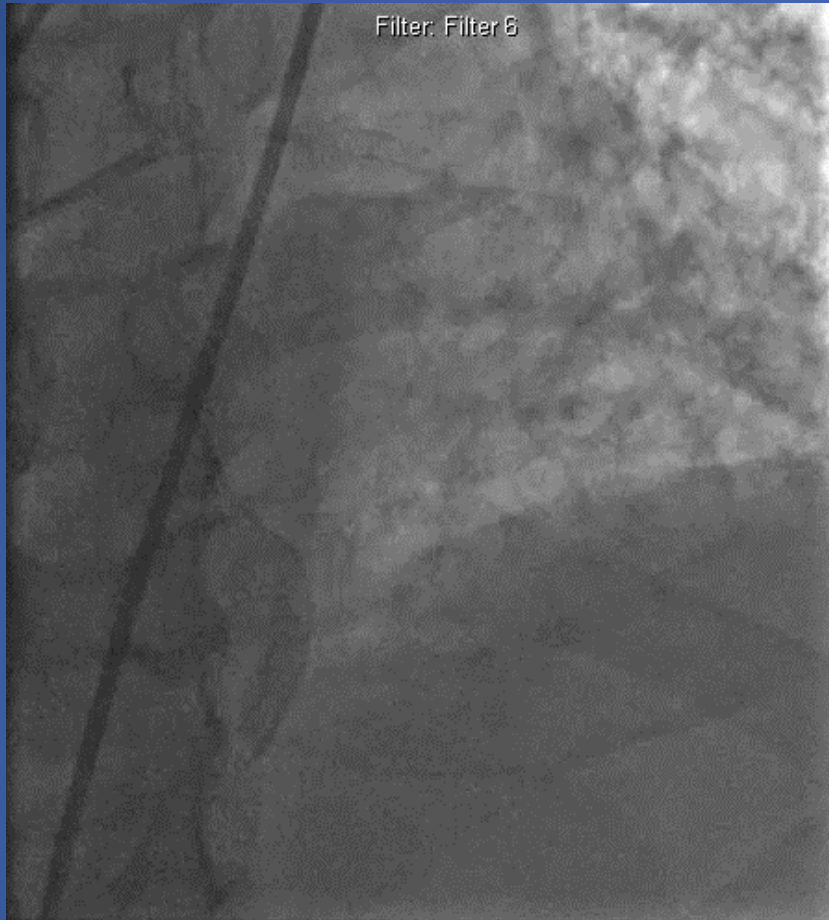
Derived, Filter: Filter 1



Treats 360° of the vessel. The diamond coated crown sands away calcium and allows healthy elastic tissue to flex away minimizing injury to the vessel.



# Final Angiography



# Conclusion

- Coronary artery calcification may prevent stent delivery and optimal stent expansion
- CAC is associated with increased risk of complications, including death, MI, TVR, and stent thrombosis
- Orbital atherectomy is a safe and effective treatment strategy for patients with severe CAC
- Low angiographic complications
- Acceptable rates of TVR







**John Wooden**

***“Failing to prepare is preparing to fail”***

